

Eosinophilic gastro-enteritis in a German shepherd dog: Clinical, Haematological and Biochemical study

*Minnat T.R.; *Al-Bassam, L.S. and **Rasheed, Y. M.

Diyala University, Faculty of Veterinary Medicine, Iraq.

*Dep. of Internal and preventive Medicine.

** Dep. of Surgery and Obstetrics.

Email: tariq8222@ yahoo.com-Mobile: 07705633515 - 07809005682.

Abstract

A 4-year-old male German shepherd dog was presented to the Vet. Clinic / Fac. Vet. Medicine / Diyala University with long past history of anorexia, chronic intermittent vomiting, hematemesis and melena. Clinical examination revealed dehydration, debilitation with generalized paleness of mucous membranes. Blood picture showed anaemia with eosinophilic leukocytosis. Biochemical parameter included mild increase in ALP, ALT and AST enzymes with normal range of creatinine and urea and a decrease in total plasma protein and increase in fibrinogen. There was an excellent animal response to treatment with Prednisolone. Recurrence of clinical signs appeared after stoppage of treatment and the condition get worse. Ultrasonographic examination revealed pathological changes in the liver and stomach of the animal. The animal died after sometime. All previous observations suggested that the case is an advanced fatal eosinophilic gastroenteritis (EG). This is the first report on canine eosinophilic gastroenteritis in Diyala Province/ Iraq.

Key word: Eosinophilic gastroenteritis, German shepherd dog.

التهاب المعدة والأمعاء اليوزيني في كلب الراعي الألماني: دراسة سريرية ، دموية وبايوكيميائية

طارق رفعت منت* ، ليلي صبحي البصام* و ياسين محمود رشيد**

* فرع الطب الباطني والوقائي كلية الطب البيطري / جامعة ديالى ، العراق. ** فرع الجراحة والتوليد البيطري

كلية الطب البيطري / جامعة ديالى ، العراق

المستخلص

أدخل كلب من نوع الراعي الألماني يبلغ من العمر 4 سنوات الى عيادة كلية الطب البيطري / جامعة ديالى. تميز تاريخ حالته المرضية باعراض مزمنة لفقدان الشهية مع تقيئ دموي منقطع و غائط اسود(ميلينا). أشار الفحص السريري الى وجود جفاف، وهن مع شحوب معظم الأغشية المخاطية. أظهرت الصورة الدموية وجود مؤشرات فقر الدم مع زيادة في عدد كريات الدم البيضاء وخصوصاً الخلايا الحمضة. كذلك لوحظ وجود انخفاض بسيط في عدد الاقراص الدموية. تضمنت المعايير البيوكيميائية زيادة طفيفة في انزيم ALP، ALT، و AST مع معدل طبيعي للكرياتين واليوريا ونقص في مستوى بروتينات الدم مع ارتفاع في مستوى الفايبرونوجين. كانت استجابة الحيوان للعلاج بالبريديزولون سريعة و واضحة. اظهرت الحالة رجوع للعلامات السريرية بعد توقف العلاج حيث ازدادت الحالة سوءاً. الفحص بالأشعة فوق الصوتية للكلب في الفترة المتقدمة

للمرض بين وجود تغيرات مرضية في الكبد والمعدة. جميع الملاحظات السابقة تشير الى أن الحالة متقدمة ومميتة بالتهاب المعدة والأمعاء اليوزيني (EG). يعتبر هذا التقرير الأول عن التهاب المعدة والأمعاء الأيوزيني للكلاب في محافظة ديالى / العراق.

الكلمات المفتاحية: التهاب المعدة والأمعاء اليوزيني، كلب الراعي الالمانى .

Introduction

Eosinophilic gastro-enteritis (EGE) is an inflammation of the Stomach and Intestine associated with eosinophilia, it is a rare, poorly understood condition as the common denominator [28]. It was first reported in humans in 1937, and was originally called 'The Hypereosinophilic Syndrome' [30]. In animals; it was first detected in cats [12]. The disease is a chronic idiopathic inflammatory condition of the intestine characterized by the presence of a mixed inflammatory infiltrate in tissue with predomination of eosinophils [26]. Causes of this disease are poorly defined, although allergens in food, migrating parasites have been suggested for induction of EG [4, 26]. Clinical signs are similar to those of other chronic gastroenteritis and may include vomiting, hematemesis, small bowel- type diarrhea, weight loss, melena and anorexia [14]. The diagnosis of eosinophilic gastroenteritis should be considered if the relevant clinical signs are present in conjunction with an elevated peripheral eosinophil count [28]. Nevertheless, eosinophilia is an inconsistent finding in dogs [16], in addition to that eosinophilia is common in animals with all kinds' of gastrointestinal diseases [16]. Treatment for canine eosinophilic enteritis is largely empirical due to the poor understanding of the etiopathogenesis and lack of therapeutic trials. Administration of corticosteroids, sulfasalazine, azathioprine, antibiotics and specific diets has been applied with transient response [2, 25]. Dogs of five years and less are usually more affected; sex predisposition has not been reported; male and female dogs are equally affected. Certain breeds of dogs are more likely to be affected as German shepherd dogs and Rottweilers [15].

Materials and Methods:

Animal:

A 4-year-old male German shepherd police dog was presented to the clinic of the Faculty of Vet . Medicine in Diyala University; with long previous history of anorexia, chronic intermittent vomiting, hematemesis and melena, which had been ongoing for several weeks . Clinical examination was carried. The dog was fully vaccinated and dewormed every 3 months with oral fenbendazole.

Samples:

Blood samples from cephalic vein were collected with and without EDTA for complete blood count and serum biochemistry, respectively.

Fecal sample was directly collected from rectum for detection of internal parasite infection.

Ultrasonigraphy:

After discontinuity of Prednisolone administration; the animal condition get worse and he was subjected to Ultrasonography using (real-time B-mode scanner (WellD ultrasound, Shenzhen well. D. Medical Electronics Co. LTD. China) .

Laboratory examination:

Blood: Blood examination was carried manually in the clinical Pathology laboratory of the Faculty; it included detection of: Hematocrit value (Hct %), hemoglobin (Hb g/dl), erythrocyte count (RBCx10⁶ / μ l), erythrocyte indices (MCV fl and MCHC g/dl), evaluation of platelet adequacy by indirect blood smear method, total and differential leukocyte count, erythrocyte sedimentation rate (ESR mm/hour), total plasma protein (TPP g/dl) and fibrinogen evaluated by heat coagulation method and manual refractometry, all were carried according to [5]. Other serum parameters as blood glucose, Serum creatinine (SCr), Urea, Alanine amino transferase (ALT), Aspartate amino transferase (AST) and Alkaline phosphatase (ALP) were measured using Spectrophotometer (CECIL2031 England) and Kits for Liver and kidney function enzymes (RANDOX Company).

Faeces:

Macroscopic examination: Sample was carefully examined for changes in color consistency, presence of mucus, fresh and digested blood, whole parasite or parasite segments.

Microscopic examination: Direct fecal smear, flotation and sedimentation concentration techniques were applied according to [13], for the detection of parasite eggs.

Results:

Clinical examination:

First admission: It revealed mild dehydration, debilitation with generalized paleness of mucous membranes. On physical examination, generalized weakness, lethargy and polypnea were observed; capillary refill time was more than 2 second. The dog showed mild pain during abdominal palpation.

After treatment with antibiotic and prednisolone with change in the diet of the dog from food pellets to chicken thighs, the animal returned to his normal condition, showed good appetite gained weight; diarrhea and vomiting stopped completely.

Second admission: After about three month of prednisolone treatment; the drug was gradually stopped, clinical signs reappeared and the animal condition get worse. In second admission the animal appeared markedly emaciated, weak and can hardly walk (Fig. 1 (A &B)). After few weeks the animal died. Unfortunately, postmortem examination was not attempted.

Ultrasonography: It revealed enlargement in the liver and spleen



A

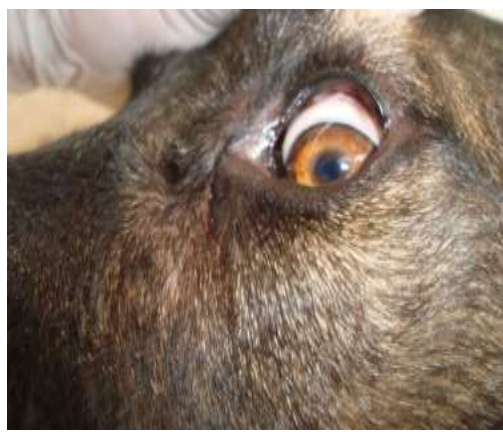

B

Fig.2: (A&B) A: Brownish red vomits with mucus (Hematemesis).
B: Tarry black feces (Melena).



A



B

Fig.1 (A &B) A: Animal showing emaciation, dullness, dehydration and weakness.
B: Paleness of ocular mucosa.

Laboratory examination:

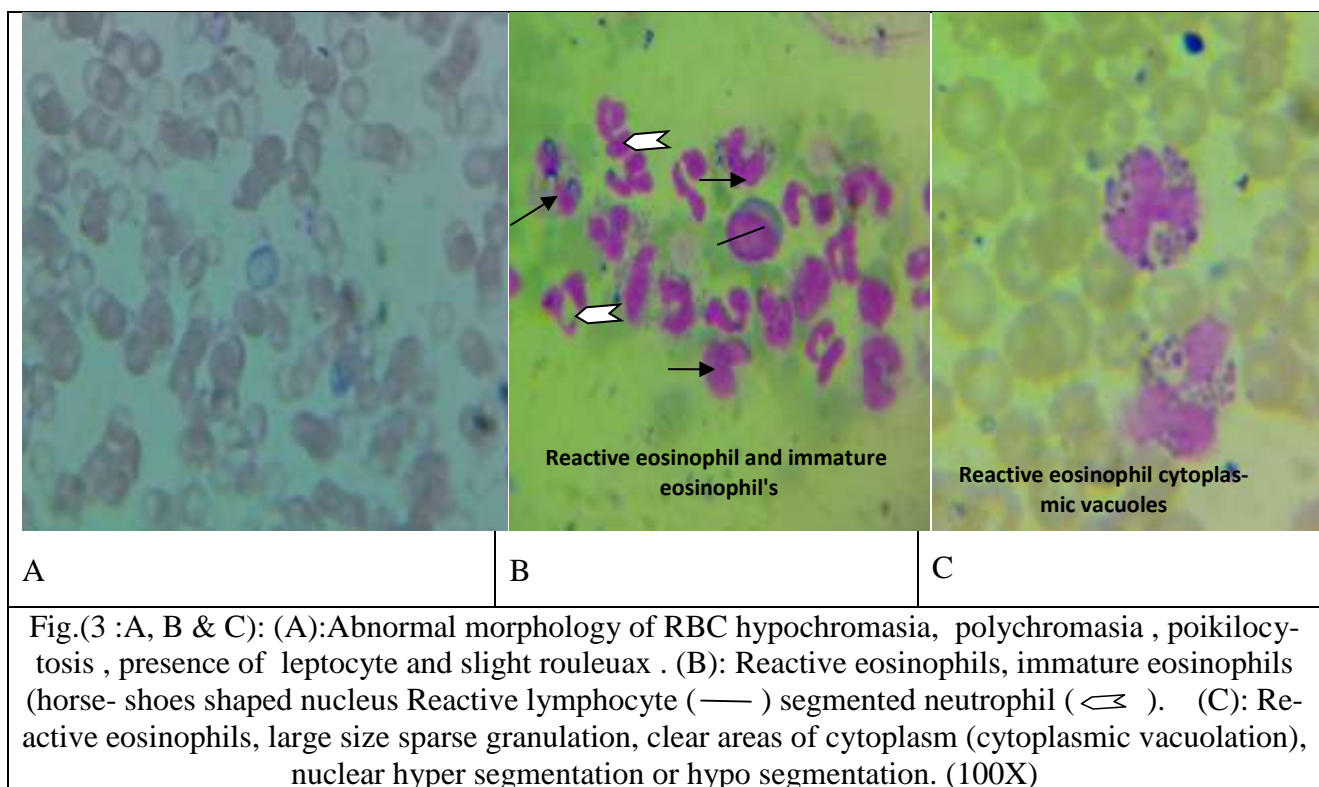
Blood examination:

Blood examination:

Revealed decrease in Htc, Hb, erythrocyte indices and platelet count. Marked eosinophilic leukocytosis with increase in total plasma protein (TPP) and fibrinogen concentration were also detected (Table -1).

Abnormalities in morphology of RBCs as anisocytosis, poikilocytosis, hypochromasia, polychromasia, presence of leptocytes with slight rouleaux formation were detected on examination of stained blood films in various periods (Fig 1-A,B & C).

1 (A &B)



Treatment:

Amoor was treated with Prednisolone (Corticosteroid), antibiotic, tonics, and rehydrating fluids . Changing in the Diet was changed from commercial dog food pellets (Company) to rice with chicken thighs. The animal health showed marked improvement immediately after the start of treatment; blood parameters showed decrease in eosinophil number with gradual increase in erythrocyte markers.

Table (1): Blood parameter

Test	Unit	Normal range	Patient 1 st visit	Patient 2 nd visit
Haematocrit (Hct)	%	35.0-52.0	23.0**	19.0**
Hemoglobin (Hb)	g/dl	12.0-18.0	7.2**	6.8**
Red blood cell (RBC)	x10 ⁶ /μl	5.4 - 7.8	3.833**	3.251**
MCV	fl	64.0 – 74.0	60.00**	58.44 **
MCH	Pg	22.0 – 27.0	18.78**	20.91**
MCHC	g/dl	34.0 – 36.0	31.3*	35.78
Platelets count	(X 10 ³ /μl)	150-500	147**	145**
Plasma protein (PP)	g/dl	6.0-7.8	5.5**	5.2**
Fibrinogen	g/dl	150-300	400*	500*
WBC	x10 ³ /μl	6.0-17.0	23.7*	24.19*
Band neutrophils	x10 ³ /μl	0.0–0.13	0	0.0
Segmented neutrophils	x10 ³ /μl	2.1–11.2	3.58	2.81
Eosinophil	x10 ³ /μl	0.0–1.2	15.642	16.870*
Basophil	x10 ³ /μL	0–0.13	0	0
Monocyte	x10 ³ /μL	0.0–1.2	950	1.26*
Lymphocyte	x10 ³ /μL	0.3–5.1	3.528	3.25
<p>1st. visit= The first admission of patient to the clinic. Normal blood parameter from (18) 2nd. visit= After 3-4 months of the first admission. *= More than normal value , **= Less than normal value</p>				

Serum biochemistry showed a mild increase in ALP, ALT and AST enzymes as well as normal range of glucose, creatinine and urea values (Table-2).

Table -2: Patient's biochemical parameter on 2nd admission.

Test	Unit	Normal range	Patient
Glucose	mmol/L	4.3 - 6.7	5.8
Urea	mmol/L	2.5 - 8.9	6.4
Creatinine	μmol/L	44 - 124	68
Alkaline phosphatase (ALP)	IU/L	10 -73	78*
Alanine aminotransferase (ALT)	IU/L	15 -58	61*
Aspartate aminotransferase (AST)	IU/L	16 - 43	46*
Referent data for(normal range MEYER and HARVEY (2004). *=- More than normal value			

Fecal examination: It was negative for all kinds of gastrointestinal parasites.

Ultrasonographic examination:

Ultrasono -graphic (US) examination was performed trans-abdominal using a real-time B-mode scanner. *Liver:* Hepatomegally with large nodule outlined by peripheral hypoechoic halo apparent, the central portion of lesion is more acrogenic and measured 42x42 mm as in figure (5). *Gallbladder:* No stone and normal size. *Spleen:* Normal in size, shape and echogenicity with no focal lesion appreciated. *Kidneys:* Both kidneys were normal in shape, size and contour. *Stomach:* Appeared with markedly thickened wall and normal motility.

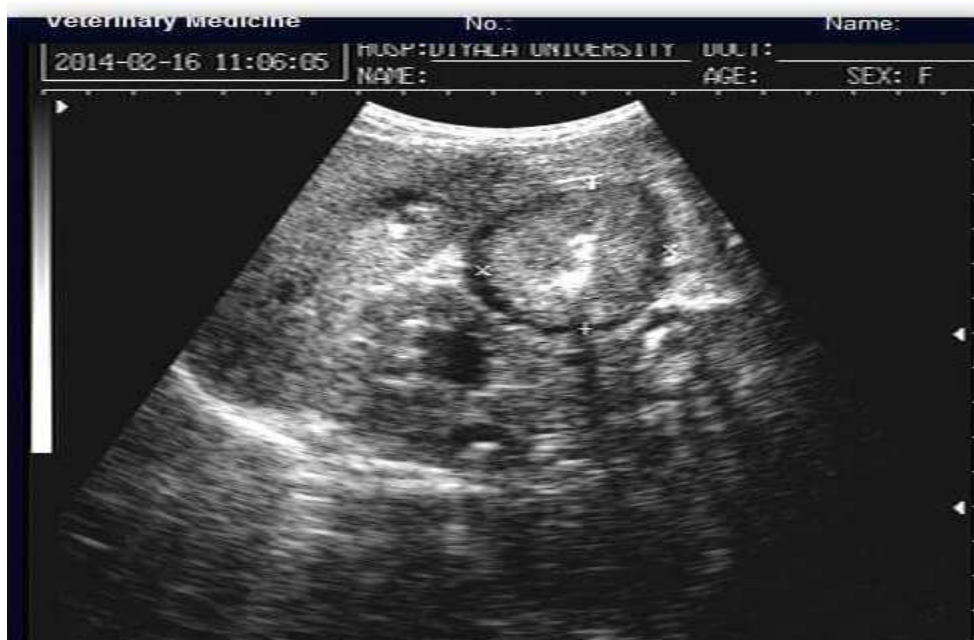

Fig.(5): Ultrasonography image (of dog liver enlarged and a large solid nodule ,rounded, outlined by peripheral hypoechoic halo apparent ,the central portion of lesion is more echogenic and measured 42x42 mm.(delineated by dotted line)

Discussion:

There are different causes of hematemesis and melena in dogs, such as infection with gastrointestinal parasites, intoxication by rodenticides and other chemicals, bacterial infections as with *Helicobacter* sp. in addition to idiopathic forms of inflammatory bowel disease [13, 1]. In the current case; marked peripheral eosinophilia with no gastrointestinal parasite infection and associated chronic long standing clinical signs of gastrointestinal bleeding as hematemesis, melena has drawn diagnosis towards eosinophilic gastroenteritis (EGE); it is a form of inflammatory bowel disease (IBD).

This was further confirmed by the rapid magical response of the dog to corticosteroid treatment. Treatment of the dog with corticosteroids was only symptomatic and relapse took place after stopping cortisone treatment although it was carried gradually. Blood examination was not attempted during treatment with cortisone. The diagnosis of EGE may be based on clinical findings and a favorable response to steroid therapy especially when histologic examination of tissues after necropsy or biopsy specimens is not attempted [6, 11]. Although IBD is the most common cause of chronic vomiting and diarrhea in the dog, diagnosis may be challenging [11].

Hematemesis, and melena observed in this case mostly resulted from gastrointestinal ulceration and bleeding in the gastro-intestinal tract this is in agreement with findings of others [13, 14,] . The coffee brown vomit is attributed to the presence of bleeding ulcers in the stomach.

Changes in haematological parameters are in agreement with [21]. The observed decrease in MCV and MCHC values (Table -1) indicates the presence of microcytic hypochromic anaemia. This type of anaemia has been reported in dogs and cats following chronic GI blood loss, as it eventually leads to iron deficiency [20, 30]. Abnormal morphology of red blood cells as anisocytosis, microcytosis, hypochromasia and polychromasia is attributed to iron deficiency associated with chronic blood loss and to the regenerative process in the bone marrow yielding immature, large red blood cells and reticulocytosis (polychromasia).

Marked, persistent eosinophilic leukocytosis is noteworthy, and it has been regarded of diagnostic value in both cats [9] and dogs [8, 21, 22, 28, and 29]. Nevertheless, some scientist considered peripheral eosinophilia as an inconsistent finding in dogs affected with EGE, claiming that, eosinophilia is common in animals with all kinds of gastrointestinal diseases [16]. In addition, peripheral eosinophilia may indicate the presence of special form of eosinophilic gastroenteritis; known as allergic eosinophilic gastroenteritis. This disorder is characterized by elevated serum levels of IgE, presence of specific IgE to some food antigens and by eosinophilia of tissue and blood [28]. Food allergies account for about 10% of all the allergies seen in dogs, being the most common cause after flea bite allergies and inhalant allergies [27] and as part of the treatment for this dog, diet was changed to chicken thighs and rice instead of the cheap, commercial dog food pellets given usually for police dogs in the province. Most eosinophils counted in blood smear of the patient were large, exhibiting

cytoplasmic vacuoles with unsegmented (band) or more than two lobes nuclei and they were considered as reactive eosinophils [23].

Inadequate number of thrombocytes was detected through examination of stained blood film, thrombocytopenia usually accompany bleeding disorders in most animals due to increase consumption [3].

Decrease in total plasma protein is mostly related to mal intestinal absorption and protein losing enteropathy usually associated with such clinical conditions. Hyperfibrinogenaemia correlates well with chronic inflammatory reaction detected in the patient; this is in agreement with findings of [17].

Normal values for serum creatinine and blood urea indicates apparently normal kidney function, this is in agreement with other's observation who reported many patients with GI haemorrhage and normal blood urea and serum creatinine concentration [20, 30]. On the other hand; a high BUN-to-creatinine ratio (>20 using conventional units) has been reported with GI haemorrhage, particularly in cases of upper GI haemorrhage [7], this elevation has been attributed to intestinal absorption of proteinaceous substances resulting from digestion of blood in the small intestine [3].

Mild elevation in liver enzymes detected in serum of the patient runs parallel with hepatic lesions detected by ultrasonographic examination. Radiographic examination and abdominal ultrasound are highly requested for the diagnosis of EGE [7]; unfortunately ultrasound examination was carried only once, at final stages of the disease. Marked thickening of gastric wall observed in this study agreed with that detected by other workers and it is highly suggestive for the presence of the disease [7, 21]. Age and breed of the affected dog are comparable with breed and age susceptibility mentioned previously [15]. Death of the dog mostly results from severe complications of the disease and failure of attempting a precise, specific treatment for the idiopathic condition, this finding is in agreement with others (1). The treatment of inflammatory bowel disease (IBD) faces numerous difficulties owing to the unknown cause of the disease [17].

Acknowledgement

Authors are thankful for lab. Assistant Walaa Mahmoud for her kind help and continuous cooperation .

References

- 1- Bauer, S.; Schaub, N.; Dommann-Scherrer, C.C.; Zimmermann, D.R.; Simon H.U. and Wegmann, W. (1996). Long-term outcome of idiopathic hypereosinophilic syndrome transition to eosinophilic gastroenteritis and clonal expansion of T cells. *Eur J Gastroenterol Hepatol*; 8:181-185.
- 2- Brignola, C.; De Simone, G.; Iannone, P.; Belloli, C.; Evangelisti, A.; Campieri, M.; Belluzzi, A.; Gionchetti, P.; Tampieri, M. and Bertinelli, E. (1992). Influence of steroid treatment's duration in patients with active Crohn's disease. *Inflammation Research*, 36, 90-92.
- 3- Coles, E.H. (1986). *Veterinary clinical pathology Textbook* 4th Ed. W.B. Saunders, Philadelphia .pp.486

- 4- Craven, M.; Simpson, J.W.; Ridyard, A.E. and Chandler, M.L. (2004). Canine inflammatory bowel disease: Retro-spective analysis of diagnosis and outcome in 80 cases (1995-2002). *Journal of Small Animal Practice*, 45, 336-342.
- 5- Dacie J.V; Imelda, B.; Michael, A. L.; Mitchell Lewis, S.M. (2006). Dacie and Lewis Practical Haematology, Basic haematological techniques. 11th.Edition, British Library Cataloguing in Publication Data. Pp 23- 53.
- 6- Easley, J. R. (1972). Gastroenteritis and associated eosinophilia in a dog. *J Am Vet Med Assoc*. 161: p.1030-1032.
- 7- Fonseca-Alves, C.E; Correa, A.G and Elias, F. (2012). Eosinophilic gastroenteritis in basset hound dog. *Open Journal of Animal Sciences* 2: 110–112.
- 8- Franklin, R.T.; Jones, B.D. and Feldman, B.F. (1986) Medical diseases of the small intestine. In: Jones, B.D. and Liska, W.D. eds. *Canine and Feline gastroenterology*. Philadelphia: WB Saunders Company, pp: 188-90.
- 9- Griffin, H.E. and LaVone, D.M. (1990). Eosinophilic enteritis in a specific – pathogen - free cat. *J Am Vet Med Assoc*. 197: 619-20.
- 10- Guilford, W.G. (1996). Idiopathic inflammatory bowel disease. In: Guilford, W.G.; Center, S.A.; Strombeck, D.R.; Williams, D.A. and Meyer, D.J. Eds., *Strombeck's Small Animal Gastroenterology*, WB Saunders, Philadelphia, 451-456.
- 11- Hayden, D.W. and Fleischman, R.W. (1977). Scirrhus Eosinophilic Gastritis in Dogs with Gastric Arteritis. *Vet. Pathol*. 24: 441-448.
- 12- Hendrick M. (1981). A spectrum of hypereosinophilic syndromes exemplified by six cats with eosinophilic enteritis. *Vet Pathol*. 18: 188-200.
- 13- Jergens, A.E. (1999). Inflammatory bowel disease: Current perspectives. *Veterinary Clinics of North America: Small Animal Practice*, 29, 501-521.
- 14- Johnson, S.E. (1992) .Canine eosinophilic gastroenterocolitis. *Seminars in Veterinary Medicine & Surgery*, 7, 145- 152.
- 15- Kleinschmidt, S.; Meneses, F.; Nolte, I. and Hewicker- Trautwein, M. (2006) Retrospective study on the diagnostic value of full-thickness biopsies from the stomach and intestines of dogs with chronic gastrointestinal disease symptoms. *Veterinary Pathology*, 43, 1000-1003.
- 16- Lilliehook, I. and Tvedten, H. (2003). Investigation of hypereosinophilia and potential treatments. *Veterinary Clinics of North America: Small Animal Practice*, 33, 1359-1378.
- 17- Malewska, K.; Rychlik, A.; Nieradka, R. and Kander, M. (2011). Treatment of inflammatory bowel disease (IBD) in dogs and cats. *Pol J Vet Sci*. 14(1):165-71. Review.
- 18- Meyer, D. and Harvey, J.W. (1998). *Veterinary Laboratory Medicine: Interpretation and Diagnosis*. 2nd Edition.
- 19- O'Briel S. (1989). Eosinophilic enteritis in an Irish setter dog. *Can Vet J*; 30: 972.

- 20- Prause, L.C. and Grauer, G.F. (1998) Association of gastrointestinal haemorrhage with increased blood urea nitrogen and BUN/ creatinine ratio in dogs: a literature review and retrospective study. *Vet Clin Pathol*, 27: 107.
- 21- Rodriguez, A.; Rodriguez, F.; Pena, L.; Flores, J.M.; Gonzalez, M. and Castano, M. (1995). Eosinophilic gastroenteritis syndrome in dog. *Veterinary Quarterly*.17:34-6. Marks SL. Management of canine inflammatory bowel disease. *Compend Contin Educ Pract Vet* 1998; 20:317–331.
- 22- Rothenberg, M.E., Hogan, S.P., (2006). The eosinophils. *Annual Review of Immunology* 24, 147-174.
- 23- Skubitz, K. M. (2004). Neutrophilic leukocytes. In: Greer J, editor. *Wintrobe's Clinical Hematology* 11th ed. Philadelphia: Lippincott Williams & Wilkins; 2004. Pp: 268-310.
- 24- Stanton, M.E. and Ronald, B.M. (1989). Gastroduodenal ulceration in dogs: retrospective study of 43 cases and literature review. *J Vet Intern Med*; 3: 238.
- 25- Stein, R.B. and Lichtenstein, G.R. (2001). Medical therapy for Crohn's disease: The state of the art. *Surgical Clinics of North America*, 81, 71-101.
- 26- Tams, T. R. (2003). Chronic diseases of the small intestine. In: Tams, T.R. Ed., *Handbook of Small Animal Gastroenterology*, Elsevier, Philadelphia, 211-250. doi:10.1016/B978-0-7216-8676-9.50011-9.
- 27- Tapp, T.; Griffin, C.E.; Rosenkrantz, W.; et al. (2002). Comparison of a commercial limited-antigen diet versus home-prepared diets in the diagnosis of canine adverse food reaction. *Veterinary Therapeutics*. 3(3): 244-251.
- 28- Triantafillidis, J.K.; Ekaterina Parasi, P. and Sklavaina, C.M. (2002). Eosinophilic gastroenteritis: Current aspects on etiology, pathogenesis, diagnosis and treatment. *ANNALS OF GASTROENTEROLOGY*, 15(2):106-115.
- 29- Van der, G.I. and Van der, J.S.L. (1987). Eosinophilic granulomatous colitis with ulceration in a dog. *J Comp Path.* ; 179-85.
- 30- Waldrop, J.E.; Rozanski, E.A.; Freeman, L.M. et al. (2003). Packed red blood cell transfusions in dogs with gastrointestinal haemorrhage: 55 cases (1999-2001). *J Am Anim Hosp*. 39: 523.